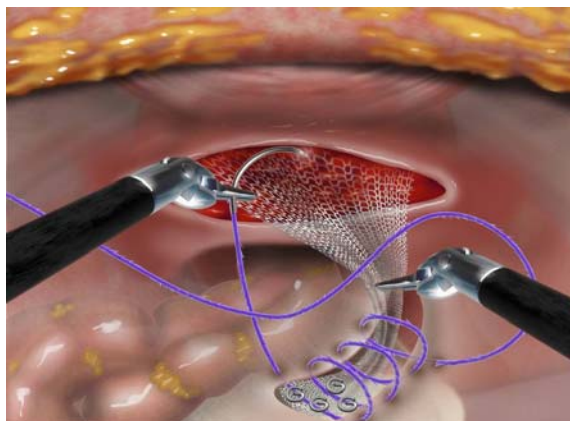


Now Available in Four New Laparoscopic / Robotic GYN codes

Experience the extraordinary in laparoscopic and robotic gynecologic procedures




In sacrocolpopexy and hysterectomy procedures, surgeons report:


- The bidirectional barbed structure “enables the surgeon to be more independent and agile” during the tedious and time-consuming task of peritoneal closure in laparoscopic sacrocolpopexy procedures.
- Ghomi A, Askari, R. 2010¹
- In a one-year retrospective analysis of 113 consecutive total laparoscopic hysterectomies, “No cases of cuff dehiscence, hematoma or cellulitis occurred.” The authors concluded that the use of the Quill™ device appears to be safe and efficient when closing the vaginal cuff in a TLH...”
- Einarsson JL, et al. 2009²



The Quill™ PDO device in peritoneal closure for the Sacrocolpopexy procedure. Angiotech, Reading, PA.

Learn more about how the Quill™ device is transforming the nature of soft tissue closure at www.angioedupro.com.

PDO – TAPER POINT		Barb Configuration	Size				
Needle	Color		4-0	3-0	2-0	0	1
 22 mm 1/2 circle	Violet	14 cm x 14 cm					RA-1088Q
 26 mm 1/2 circle	Violet	10 cm x 10 cm					RA-1078Q
	Violet	14 cm x 14 cm					RA-1079Q
 36 mm 1/2 circle	Violet	7 cm x 7 cm					RX-1068Q
	Violet	14 cm x 14 cm					RX-1069Q

POLYPROPYLENE – TAPER POINT		Barb Configuration	Size
Needle	Color		1
 22 mm 1/2 circle	Clear	14 cm x 14 cm	JA-1050Q

¹ Ghomi A, Askari, R. Use of a bidirectional barbed suture in robot-assisted sacrocolpopexy. *J Robotic Surg*. Published online 2010: <http://springerlink.com/content/r22q11555V123755/fulltext.html>.

² Einarsson, JL, et. Al. The use of bidirectional barbed suture in laparoscopic myomectomy and total laparoscopic hysterectomy: an evaluation of safety and clinical outcomes. *J Minim Invasive Gynecol*. 2009;16:S28-S29.